

Management and Progression of Arginase 1 Deficiency Over 2 Decades of Follow-Up

Deborah Marsden, MBBS, FAMCGG, MRCP(UK)¹ and Alexandra Eaton²

¹Boston Children's Hospital, Department of Genetics and Genomics, Boston, Massachusetts, United States; ²Parent/caregiver and patient advocate, Marshfield, Massachusetts, United States

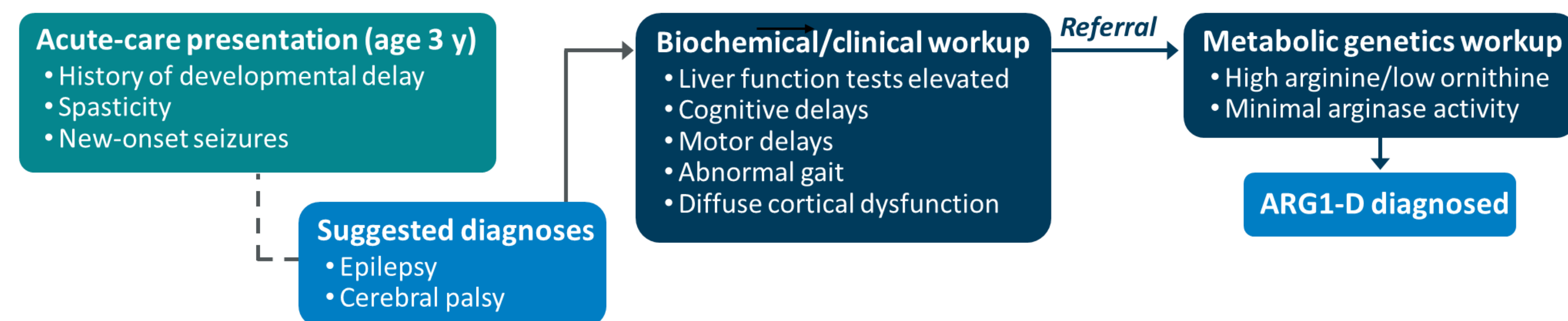
Introduction

- Arginase 1 Deficiency (ARG1-D) is a debilitating autosomal recessive inborn error of metabolism with significant, progressive neurologic manifestations driven by high arginine levels that result from impaired or absent arginase activity¹⁻⁴
 - Other metabolic disruptions include elevated guanidino compounds, glutamine, and ammonia⁵
 - Liver dysfunction, indicated by increased transaminases and, rarely, hepatomegaly may also occur^{5,6}
- Progressive spasticity, usually affecting the lower extremities, is a distinguishing feature of ARG1-D and frequently leads to gait abnormalities and impaired mobility. Other characteristic manifestations include developmental delay, seizures, and cognitive impairment^{7,8}
- ARG1-D is unlike other urea cycle disorders (UCDs) in that onset of manifestations rarely occurs in the first weeks or months of life and hyperammonemic crisis is comparatively rare in the majority of patients^{2,7}
- Here, we describe a complex adult patient who was diagnosed with ARG1-D at 3 years of age and who, through nearly 20 years of follow-up, has experienced both characteristic and atypical manifestations of his disorder

Medical History and Disease Course

- The patient is a Caucasian male who presented to acute care at 3 years of age with new-onset seizures and was diagnosed with ARG1-D after referral to metabolic genetics (Figure 1). Diagnosis was based on observation of high plasma arginine, low plasma ornithine, and erythrocyte arginase activity of 10 $\mu\text{mol/g Hgb/h}$ (~1% of normal control)

Figure 1. Diagnosis



- Standard-care management was initiated. Owing to continued hyperammonemia, liver dysfunction, and progression of manifestations, several additional interventions have been introduced over time (eg, ornithine, sodium phenylbutyrate, botulinum toxin). The patient has experienced a complex and difficult clinical course, including numerous hyperammonemic crises and a metabolic coma (Figure 2)

Figure 2. Ammonia Levels Over Time

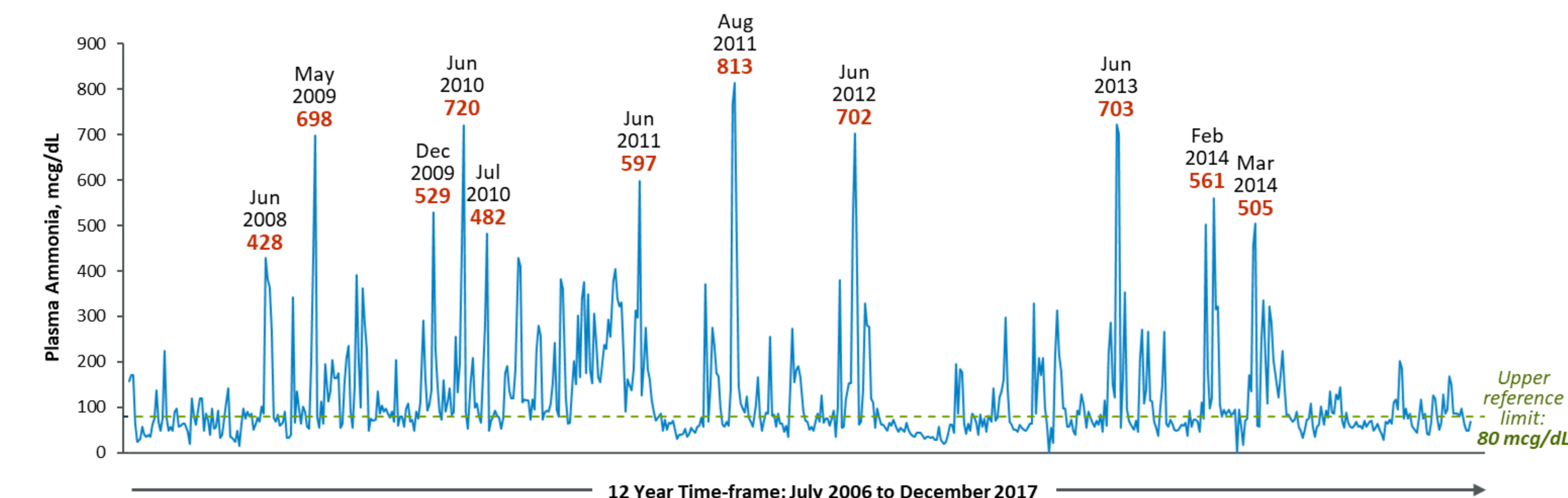
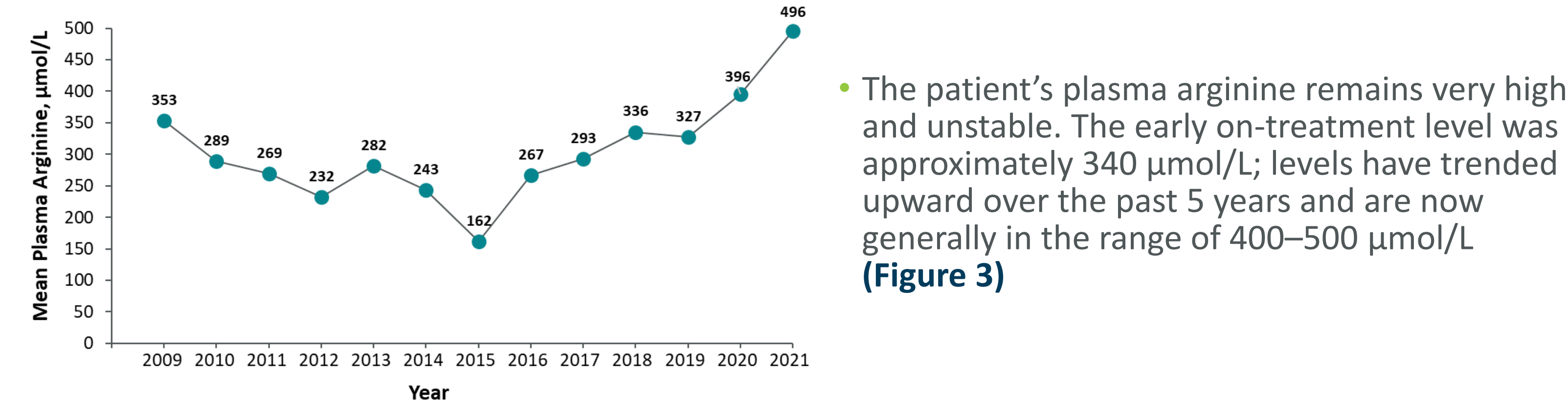


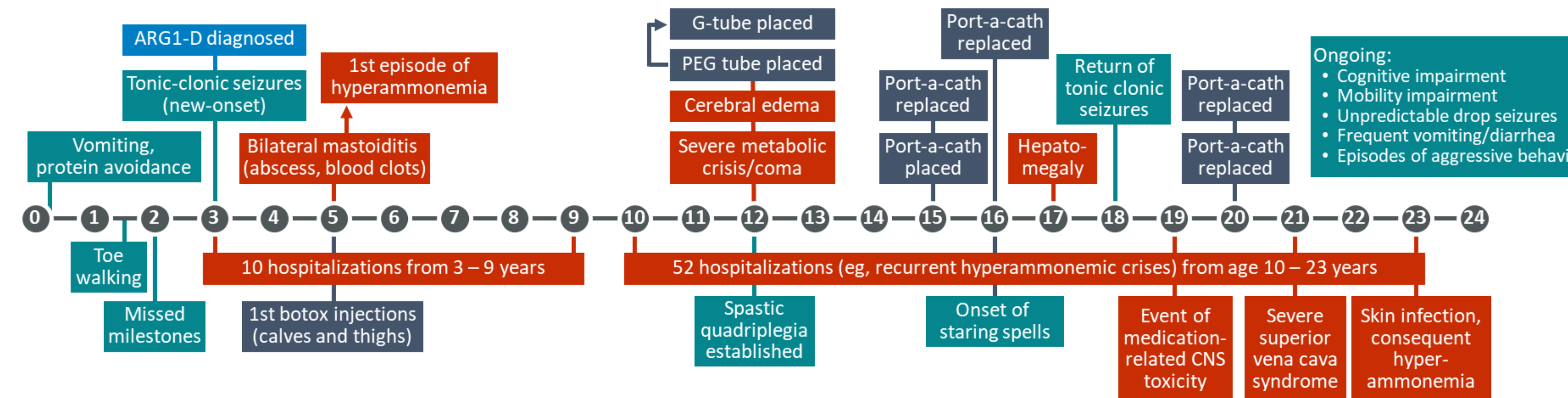
Figure 3. Mean Plasma Arginine Level Over the Past 12 Years



Patient and Caregiver Perspective

- The patient has had a complicated journey; he has complex medical issues and is very sensitive to changes in nutrition or medication (Figure 4)
 - He has been hospitalized for hyperammonemia many times. After a severe metabolic crisis with hyperammonemia, mental status changes, and a coma, he had a G-tube placed to help manage his nutrition and medication
 - Placement of a port-a-cath was required for easy access for labs and administration of intravenous medications. Particularly during crises, blood draws and IV placement were difficult, and placement of numerous femoral lines increased risk of a blood clot and potentially devastating complications. Although the port-a-cath has required replacement several times, it has made managing blood draws and medications much easier
 - He has continued to progress over time and his arginine has been getting higher over the past several years

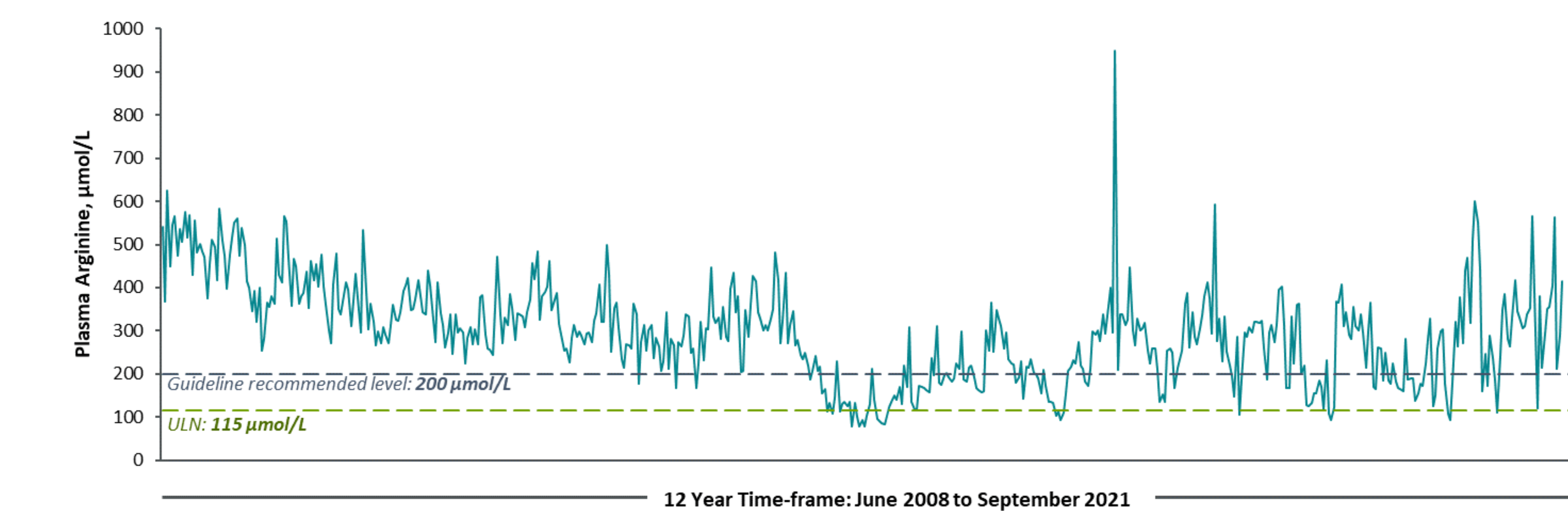
Figure 4. Clinical Course



- His plasma arginine is difficult to control, and fluctuations affect his functional ability and demeanor (Figure 5)
 - Higher arginine levels coincide with episodes of irritability or aggression and worsening of verbal impairment
 - Verbal ability and mobility improve when arginine levels trend lower



Figure 5. Plasma Arginine Time-Course



- He requires home care and assistance with activities of daily living, and also receives behavioral therapy, physical therapy, occupational therapy, and speech therapy. Because of the treatment and support he receives, he has been able to interact with peers, participate in group activities, and be a part of the community
- Managing the patient's nutrition, medication, and overall health is challenging, and has not prevented progression over time. There is an urgent need for better treatment options for patients with ARG1-D



Clinical Perspective

- This patient's clinical course is consistent with the typical manifestations, natural history, and progressive nature of ARG1-D; however, he also demonstrates atypical manifestations and complications, such as hepatomegaly and numerous hyperammonemic crises
- His clinical and biochemical profile demonstrates the role of arginine in both long-term progression and acute worsening of ARG1-D manifestations
- Through 2 decades of maximum treatment with the best-available care from a multispecialty team, this patient has experienced persistently elevated arginine and chronic, debilitating progression
 - This case illustrates the limitations of the current standard of care and the high unmet medical need in ARG1-D
 - New therapies that provide effective arginine reduction and delay or prevent progression are needed to improve patient outcomes

References 1. Carvalho DR, et al. *Pediatr Neurol*. 2012;46(6):369-374. 2. Huemer M, et al. *J Inherit Metab Dis*. 2016;39(3):331-340. 3. Diez-Fernandez C, et al. *Hum Mutat*. 2018;39(8):1029-1050. 4. Häberle J, et al. *J Inherit Metab Dis*. 2019;42(6):1192-1230. 5. Sun A, et al. Arginase deficiency. In: Adam MP, et al, eds. *GeneReviews*® [Internet]. University of Washington, Seattle; 2004. 6. Scaglia F & Lee B. *Am J Med Genet C Semin Med Genet*. 2006;142(2):113-120. 7. Burrage LC, et al. *Hum Mol Genet*. 2015;24(22):6417-6427. 8. Häberle J, et al. *Orphanet J Rare Dis*. 2012;7:32.

Disclosure Dr Marsden has no relevant relationships to disclose. Ms Eaton has participated in patient advocacy advisory boards supported by Aeglea.

Acknowledgments Medical writing support was provided by Heather Starkey, PhD, from The Curry Rockefeller Group, LLC (Tarrytown, NY), and was funded by Aeglea.